

Julie A. Theurer, M.Cl.Sc.
Doctoral Program in
Rehabilitation Sciences
School of Communication
Sciences and Disorders
University of Western Ontario
London, Ontario Canada

Jennifer L. Johnston, M.Sc.
School of Communication
Sciences and Disorders
University of Western Ontario
London, Ontario Canada

Donald H. Taves, MD
Department of Medical
Imaging
University of Western Ontario
London, Ontario Canada
Department of Radiology
St. Joseph's Health Centre
London, Ontario Canada

David Bach, MDCM, MFA,
FRCPC
Department of Medical
Imaging
University of Western Ontario
London, Ontario Canada
Department of Radiology
London Health Sciences
Centre
University Campus
London, Ontario Canada

Vladimir Hachinski, MD
Schulich School of Medicine
and Dentistry
Department of Clinical
Neurological Sciences
Department of Physiology
and Pharmacology
University of Western Ontario
London, Ontario Canada

Ruth E. Martin, M.H.Sc.,
Ph.D.
School of Communication
Sciences and Disorders
Department of Physiology
and Pharmacology
Department of
Otolaryngology
University of Western Ontario
London, Ontario Canada

■ Swallowing after Right Hemisphere Stroke: Oral versus Pharyngeal Deficits

■ La déglutition après un accident vasculaire cérébral à l'hémisphère droit : déficiences et pharyngées

Julie A. Theurer
Jennifer L. Johnston
Donald H. Taves
David Bach
Vladimir Hachinski
Ruth E. Martin

Abstract

Although previous studies have attempted to identify distinct patterns of dysphagia following unilateral hemispheric stroke, the relationships between lesion sites and swallowing dysfunction remain unclear. In particular, swallowing deficits resulting from right hemisphere stroke remain poorly understood. The present study employed a case report design to examine the oral and pharyngeal phase deficits in swallowing following right hemisphere stroke. Lateral-view videofluoroscopic images were obtained from six subjects following right hemisphere stroke as they performed swallowing trials with various bolus consistencies (i.e., thin liquid, thick liquid, and paste). Each swallow was evaluated on 17 oral phase, and 17 pharyngeal phase physiologic swallowing parameters. Results indicated that, whereas all patients exhibited both oral and pharyngeal phase swallowing deficits, the majority of patients showed relatively greater oral phase than pharyngeal phase impairment. In addition, patterns of swallowing deficits were highly variable across individuals, particularly for the pharyngeal phase. These findings suggest that oral phase swallowing impairment can be a prominent feature of right hemisphere stroke. Thus, swallowing assessment in patients with right hemisphere stroke should emphasize both oral and pharyngeal phases. Instrumental techniques can provide valuable insights into swallow pathophysiology in this population.

Abrégé

Bien que des études aient déjà tenté d'identifier des profils particuliers de dysphagie survenue à la suite d'un accident vasculaire cérébral (AVC) unilatéral, les liens entre l'emplacement des lésions et les troubles de déglutition restent flous. On comprend notamment encore mal les troubles de déglutition causés par un AVC à l'hémisphère droit. La présente recherche se fonde sur un devis de cas uniques et examine les déficiences orales et pharyngées de la déglutition après un AVC à l'hémisphère droit. On a obtenu des images vidéofluoroscopiques latérales de six personnes ayant subi un AVC à l'hémisphère droit. Ces images les montrent pendant qu'elles essaient d'avaler des aliments de consistance différente (p. ex. : liquide clair, liquide épais et purée). On a évalué chaque tentative de déglutition en fonction de 17 paramètres physiologiques de la phase orale et de 17 paramètres physiologiques de la phase pharyngée. Les résultats indiquent que, bien que tous les patients aient montré des troubles de déglutition à la phase orale autant que pharyngée, la majorité d'entre eux avaient une déficience relativement plus prononcée dans la phase orale. De plus, les déficiences de la déglutition tendent à être très variables d'une personne à l'autre, surtout dans la phase pharyngée. Ces résultats suggèrent qu'une déficience de la phase orale de la déglutition dans la phase orale serait une caractéristique dominante d'un AVC à l'hémisphère droit. Par conséquent, l'évaluation de la déglutition chez les patients ayant subi un AVC de ce type doit mettre l'accent sur les phases orale autant que pharyngée. Les méthodes techniques peuvent fournir de l'information valable sur la pathophysiologie de la déglutition chez cette population.

Key Words: deglutition, deglutition disorders, cerebrovascular accident, fluoroscopy

Introduction

Swallowing is a complex behaviour that is thought to be controlled primarily through a central network located in the brainstem (Jean, 1990). Afferent inputs trigger the activity of this medullary swallowing centre, with the neuronal network then enacting a coordinated, stereotyped sequence of motor events (Jean, 1990; Miller, 1982, 1999). However, mounting evidence from both electrophysiological and clinical studies has pointed toward the importance of the cerebral cortex in swallowing regulation (for review, see Martin & Sessle, 1993 and Miller, 1999). Of particular interest, human clinical studies have revealed that significant swallowing impairments can result subsequent to hemispheric stroke, either unilateral or bilateral, without concomitant involvement of the brainstem (Barer, 1989; Gordon, Hower, & Wade, 1987; Horner & Massey, 1988; Horner, Massey, Riski, Lathrop, & Chase, 1988; Veis & Logemann, 1985).

Numerous studies have been aimed at elucidating the relationship between unilateral stroke location and patterns of swallowing impairments. Robbins and Levine (1988) reported an association between lesions of the left cerebral cortex and oral stage deficits, while right cerebral cortical lesions were found to be associated with pharyngeal deficits. In a subsequent study, Robbins, Levine, Maser, Rosenbek and Kempster (1993) identified several durational and descriptive swallowing measures that differed significantly between individuals following left and right hemispheric stroke. These two studies have fostered the belief that left hemispheric stroke is associated with greater oral stage deficits, while right hemispheric stroke is associated more closely with pharyngeal stage deficits. However, several other studies have failed to fully substantiate this relationship (Alberts, Horner, Gray, & Brazer, 1992; Chen, Ott, Peele, & Gelfand, 1990; Daniels & Foundas, 1999; Irie & Lu, 1995; Johnson, McKenzie, Rosenquist, Lieberman, & Sievers, 1992; Veis & Logemann, 1985). For example, Veis and Logemann (1985) reported that hemispheric stroke location did not predict particular types of swallowing abnormalities. Rather, reduced lingual control (i.e., oral stage), and delayed swallowing reflex and reduced pharyngeal peristalsis (i.e., pharyngeal stage), were common outcomes of stroke, regardless of lesion lateralization. Additionally, in a small group of subjects with left subcortical strokes, mild deficits were present in both the oral and pharyngeal stage of swallowing (Logemann et al., 1993). Oral dysmotility (i.e., delayed initiation of oral transfer, and groping, effortful lingual movements) has been reported to be of equal frequency in patients with left and right hemisphere stroke (Daniels, Foundas, Iglesia, & Sullivan, 1996), and lingual discoordination has been shown to occur following both left and right hemisphere stroke (Daniels, Brailey, & Foundas, 1999). Furthermore, other studies have failed to find a clear relationship between the prevalence of aspiration, or other pharyngeal abnormalities, and the side of stroke (Alberts et al., 1992; Chen et al., 1990; Daniels & Foundas, 1999; Irie & Lu, 1995; Johnson et al., 1992). Although Irie and Lu (1995) also failed to find a

distinct correlation between site of the stroke (left vs. right) and the prevalence of oral and pharyngeal dysfunction, their results did indicate that left stroke was more prone to affect the oral stage of swallowing, while right stroke was more likely to impair both stages of the swallow.

The notion that right hemisphere stroke may impact both the oral and pharyngeal stages of swallowing is an interesting finding that warrants further exploration. The various oral and pharyngeal deficits that are exhibited following right hemisphere stroke remain relatively unexplored. While some data exist regarding lingual coordination, oral and pharyngeal dysmotility, and aspiration, there is little understanding of the breadth of physiological swallowing parameters in the oral and pharyngeal stages that are impacted by right hemisphere stroke.

Additionally, the research in this area has been dominated by group comparison studies. Certainly, large sample studies have the power necessary to identify relationships between stroke lateralization and swallowing deficit patterns, if they exist. However, as noted above, this type of research has not yielded a clear picture of the relationship between dysphagia profile and stroke location. One reason for this lack of clarity may relate to intersubject variation in swallowing performance following stroke, and, perhaps among healthy elderly. Although high intersubject variability is likely in this population, few case reports have appeared in the literature. Thus, the variability of swallowing patterns within this population remains poorly understood.

The aim of this preliminary study was to further elucidate the specific swallowing deficits associated with unilateral right hemispheric stroke in an attempt to ascertain whether the swallowing difficulties associated with such infarcts result in pharyngeal stage abnormalities primarily, or whether a pattern of both oral and pharyngeal deficits is more common. A case report design was employed in order to address swallowing variation across individuals following stroke in the right hemisphere.

Methods

Subjects

Six individuals (age, 69.3 ± 13.1 years) who exhibited dysphagia within the first week following a right hemisphere stroke participated in this investigation. Subjects were recruited through purposive sampling. Lesion information and demographic data are summarized in Table 1. Stroke location was determined with computed tomography (CT) on the day of hospital admission. Swallowing impairment in these subjects was determined with a clinical swallowing assessment and/or a standard videofluoroscopic swallow study (VFSS; Logemann, 1998). All patients were studied within 5 to 40 days (mean: 15 days) following the onset of the stroke. Four subjects were right handed (S1, S2, S4, S6); handedness for the remaining two subjects was unknown. Subjects gave written informed consent before participating in the study. The study was approved by the

Table 1
Stroke Subject Demographics

Subject	Age	Gender	Stroke location	Modified barium swallow: days post stroke	Dysphagia profile
S1	68	F	R Middle cerebral artery territory; R lacunar involving corona radiata	11	Oral deficits > pharyngeal deficits; Decreased tongue strength, coordination, and range of motion; Good awareness of post-swallow residue.
S2	67	M	R Middle cerebral artery involving mid/high frontal and parietal lobes; angular gyrus and supramarginal gyrus in inferior parietal lobe	6	Pharyngeal deficits > oral deficits; Decreased tongue strength, coordination and range of motion; Difficulty initiating and coordinating pharyngeal phase; Poor awareness of post-swallow residue.
S3	71	F	R lacunar	6	Oral deficits > pharyngeal deficits; Decreased control of bolus; Decreases tongue strength and range of motion with increased viscosity
S4	91	F	R lacunar including posterior internal capsula, into corona radiata	5	Oral deficits > pharyngeal deficits; Decreased tongue strength and range of motion; Decreased coordination of pharyngeal phase
S5	50	M	R Middle cerebral artery territory including posterior 2/3 of insular cortex	22	Pharyngeal deficits > oral deficits; Decreased lingual strength and range of motion; Decreased pharyngeal strength and coordination; Poor awareness of post-swallow residue; Several episodes of aspiration

with a Siemens's high-scan camera and recorded on S-VHS videotape at a rate of 30 frames per second using a Panasonic model 7300 videocassette recorder. The VFSSs were analyzed by two trained judges (a speech-language pathologist and a graduate student in speech-language pathology) who did not have knowledge of the patient's stroke localization. Videotapes were replayed on a Panasonic model AG-7350 videocassette recorder and viewed on a Trinitron RGB monitor, model PVM-1351Q. Fluoroscopic data were analyzed in real-time and slow motion. Each swallow was evaluated on 34 physiologic swallow abnormalities (17 in the oral and 17 in the pharyngeal stage) that reflect the major physiological events and bolus flow characteristics of impaired swallowing (adapted from Dodds, Logemann, & Stewart, 1990; Dodds, Stewart, & Logemann, 1990; Logemann, 1998). A binary rating system was used to evaluate whether each oral stage and pharyngeal stage abnormality was either present or absent, based on an operational definition for each (see Appendix A). For the purpose of this study, severity of the swallowing deficits was not rated.

University of Western Ontario Review Board for Health Sciences research involving human subjects.

Data Collection and Analysis

A VFSS was performed with each patient in the erect lateral position. The fluoroscopic tube was focused on the oral cavity from the lips anteriorly to the pharyngeal wall posteriorly, and from the nasopharynx superiorly to below the larynx inferiorly. Each subject was administered 2- and 5-ml aliquots of thin liquid barium (i.e., Unibar-100 barium, concentration 35% weight/volume), thickened liquid barium, and barium of a paste consistency (i.e., pudding) from a plastic teaspoon, and was instructed to swallow upon verbal command. Two repetitions of each volume and consistency combination were obtained, as tolerated by the subject, beginning with 2ml thin liquid. Fluoroscopic data were obtained

Results

Deglutition was evaluated by VFSS in 6 patients with lesions of the right hemisphere, with a total of 69 swallows collected for analysis (Figure 1). All patients exhibited deficits in both the oral and pharyngeal phases of swallowing. The most frequently occurring oral stage swallowing abnormalities were oral residue (66/69), impaired tongue to palate/posterior pharyngeal wall (PPW) contact (46/69), impaired tongue stripping wave (45/69), and impaired tongue propulsive action (44/69). The most frequently occurring pharyngeal stage swallowing abnormalities were vallecular residue (60/69), reduced closure of the laryngeal vestibule (35/69), PPW residue (33/69), and pyriform sinus residue (29/69).

Although all patients presented with right hemisphere stroke, the patterns of oral and pharyngeal swallowing deficits varied considerably across individuals (Figure 2).

Subject 1

Subject 1 (S1) completed 12 swallows (4 thin liquid, 4 thick liquid, 4 paste). The most frequently occurring oral stage deficits were repetitive tongue pumping (11/12), impaired tongue stripping wave (11/12), oral residue (11/12), and decreased tongue to palate/PPW contact (9/12). The most frequently occurring pharyngeal stage deficits identified were vallecular residue (12/12) and delayed pharyngeal phase (6/12). Overall, S1 presented with a swallowing pattern of more frequent oral stage abnormalities than pharyngeal stage deficits, characterized by decreased lingual coordination and range of motion, and difficulty initiating the pharyngeal phase. These deficits resulted in residue in the oral cavity and pharynx, which was more pronounced with increasing viscosity.

Subject 2

Subject 2 (S2) completed 11 swallows (4 thin liquid, 4 thick liquid, 3 paste). The most frequently occurring oral stage deficits were oral residue (11/11), premature spillage (7/11), impaired tongue propulsion (7/11), and decreased tongue to palate/PPW contact (7/11). The most frequently occurring pharyngeal stage deficits were increased pharyngeal transit time (11/11), reduced pharyngeal peristalsis (11/11), pyriform sinus residue (11/11), impaired upper esophageal sphincter (UES) opening (11/11), and delayed triggering of the pharyngeal swallow (9/11). S2 presented with a pattern of more frequent pharyngeal phase deficits than oral phase deficits, although the oral stage was also impaired significantly. This subject's swallow can be characterized by decreased lingual coordination and range of motion, with difficulty initiating and coordinating the pharyngeal phase of the swallow, leading to generalized oral and pharyngeal stasis and increased transit times.

Subject 3

Subject 3 (S3) completed 11 swallows (4 thin liquid, 3 thick liquid, 4 paste). The most frequently occurring

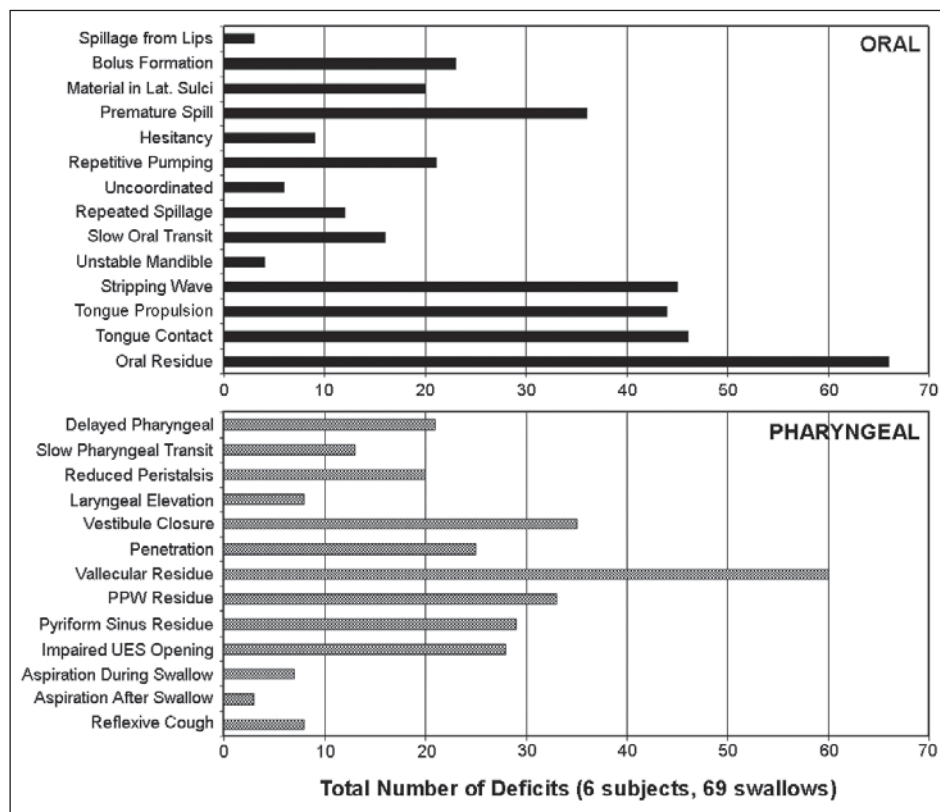


Figure 1. Number of oral phase (upper graph) and pharyngeal phase deficits (lower graph) summed over repetitions of thin liquid, thick liquid and pudding swallows for 6 subjects (69 swallows).

oral abnormalities were oral residue (11/11), premature spillage (7/11), and difficulty with bolus formation (6/11). The most frequently occurring pharyngeal abnormality was vallecular residue (9/11). Overall, S3 presented with a swallowing profile that was characterized by more difficulty in the oral phase, with particular problems controlling the bolus during oral preparation. Decreased lingual strength and range of motion became more apparent with increases in viscosity.

Subject 4

Subject 4 (S4) completed 12 swallows (4 thin liquid, 4 thick liquid, 4 paste). The most frequently occurring oral deficits were reduced tongue to palate/PPW contact (12/12), impaired tongue propulsive action (11/12), premature spillage (10/12), oral residue (10/12), and impaired tongue stripping wave (6/12). The most frequently occurring pharyngeal deficits were decreased laryngeal vestibule closure (11/12) and vallecular residue (11/12). S4 presented with a pattern of more frequent difficulties in the oral phase versus the pharyngeal phase of swallowing with decreased lingual strength and range of motion, as well as decreased coordination of the pharyngeal phase.

Subject 5

Subject 5 (S5) completed 11 swallows (3 thin liquid,

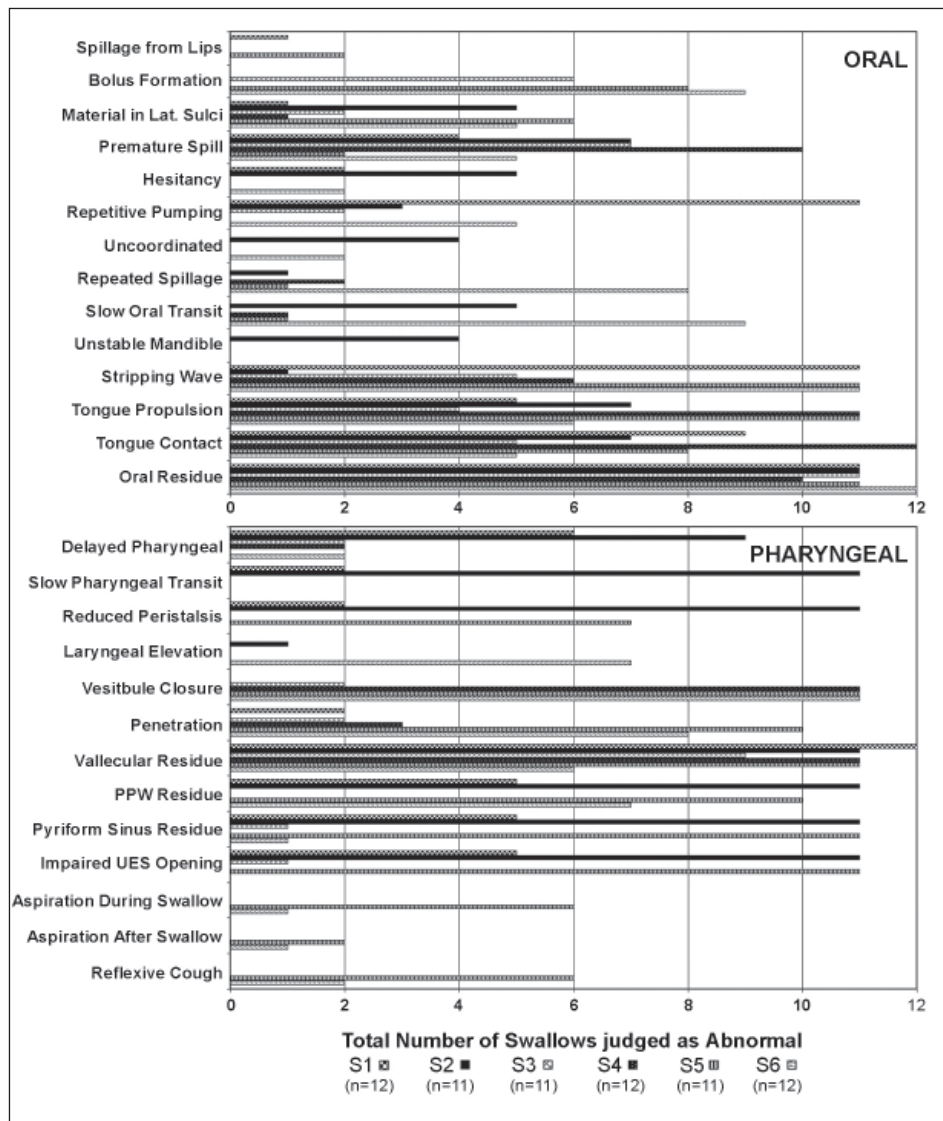


Figure 2. Number of Oral and Pharyngeal Phase Parameters judged as Abnormal, Individual data.

4 thick liquid, 4 paste). The most frequently occurring oral phase deficits were impaired stripping wave (11/11), impaired tongue propulsive action (11/11), oral residue (11/11), reduced tongue to palate/PPW contact (8/11), difficulty forming a bolus (8/11), and material in the lateral sulci (6/11). The most frequent pharyngeal phase abnormalities were decreased laryngeal vestibule closure (11/11), vallecular residue (11/11), pyriform sinus residue (11/11), impaired UES opening (11/11), laryngeal penetration (10/11), PPW residue (10/11), reduced pharyngeal peristalsis (7/11), aspiration during the swallow (6/11), and impaired/absent reflexive cough following aspiration (6/11). While this subject did demonstrate oral phase deficits, more pharyngeal stage swallowing abnormalities were noted. Lack of response to penetration, aspiration, and accumulating residue suggested reduced oral and pharyngeal sensation. S5 experienced several episodes of

aspiration across all consistencies.

Subject 6

Subject 6 (S6) completed 12 swallows (4 thin liquid, 4 thick liquid, 4 paste). The most frequently occurring oral deficits were oral residue (12/12), impaired tongue stripping wave (11/12), difficulty forming a bolus (9/12), slow oral transit time (9/12), and impaired tongue propulsive action (6/12). The most frequent pharyngeal deficits were decreased closure of the laryngeal vestibule (11/12), laryngeal penetration (8/12), PPW residue (7/12), decreased laryngeal elevation (7/12), and vallecular residue (6/12). Although oral phase deficits were more numerous than pharyngeal phase problems, the pharyngeal phase impairment was significant as it included reduced airway protection. Spontaneous repeat swallows occurred in response to oral and vallecular residue. S6 experienced two episodes of trace aspiration.

Discussion

In this small patient sample, swallowing following right hemisphere stroke was characterized by patterns of both oral phase and pharyngeal phase deficits. While some subjects (2/6) exhibited more frequent deficits in the pharyngeal stage compared to the oral stage of swallowing, the majority (4/6) showed more frequent oral stage swallowing impairments. Although

these findings differ from previous reports that right hemisphere damage results in greater pharyngeal than oral swallowing impairments (Robbins & Levine, 1988; Robbins et al., 1993), they are consistent with other studies that have failed to identify a clear association between oral versus pharyngeal stage deficits and stroke lateralization (Alberts et al., 1992; Chen et al., 1990; Johnson et al., 1992; Veis & Logemann, 1985). These findings also support two studies that identified the co-occurrence of oral and pharyngeal deficits following right hemisphere stroke (Daniels & Foundas, 1999; Irie & Lu, 1995).

This study is the first to report on a diverse range of swallowing deficits following unilateral hemispheric stroke. Oral stage deficits seen in all subjects included material in the lateral sulci, premature spill, impaired tongue stripping wave, impaired tongue propulsive action, impaired tongue to palate/PPW contact, and oral residue.

An unexpected finding was the frequency of deficits related to bolus preparation and manipulation. Typically, the preparation of the bolus for swallowing is considered to be under volitional control, and thus, associated with the left hemisphere (Robbins & Levine, 1988; Veis & Logemann, 1985). However, in this group of subjects with right hemisphere lesions, difficulty with bolus preparation was quite common. This finding supports the results of a study by Daniels and colleagues, who reported that hemisphere lateralization did not predict the occurrence of lingual discoordination (Daniels et al., 1999).

In the pharyngeal phase, only the presence of vallecular residue was universal in this population. Aside from this commonality, the patterns of pharyngeal deficits were highly individual despite the fact that all subjects had a lesion lateralized to the right hemisphere.

Although the sample is small, it is interesting to note that 3/3 patients with lacunar infarcts demonstrated oral impairment with greater frequency than pharyngeal impairment, whereas 2/3 patients with cortical stroke showed more frequent pharyngeal swallowing abnormalities. Thus, in addition to hemispheric differences, the cortical versus subcortical distinction may be a useful way of interpreting swallowing patterns post-stroke.

Electrophysiologic and functional imaging studies have implicated a distributed network of cortical and subcortical brain regions in the initiation and regulation of swallowing (Martin & Sessle, 1993; Hamdy, Mikulis et al., 1999; Hamdy, Rothwell et al., 1999; Martin, Goodyear, Gati, & Menon, 2001). These sites include the primary sensorimotor cortical orofacial representation, as well as orofacial association areas (Hamdy, Mikulis et al., 1999; Hamdy, Rothwell et al., 1999; Martin et al., 2001; Martin et al., 2004). Indeed, swallowing and voluntary tongue movement have been shown to activate overlapping, though distinct, regions of sensorimotor cortex in both hemispheres (Martin et al., 2004). Imaging studies have also suggested that the right and left hemispheres make differential contributions to swallowing control. The sensorimotor cortical swallowing representation appears to be significantly lateralized within individual subjects (Hamdy, Mikulis et al., 1999; Hamdy, Rothwell et al., 1999; Martin et al., 2001; Martin et al., 2004; Mosier et al., 1999), with 60% of right-handed, healthy subjects showing lateralization of the postcentral gyrus toward the left hemisphere (Martin et al., 2004). Given this neurophysiologic evidence, it might be anticipated that some individuals would exhibit oral stage swallowing deficits following right hemisphere stroke. Additionally, the variability in hemispheric lateralization for swallowing, as well as the distributed nature of the cortical swallowing network, fit with the current finding of substantial intersubject variability in swallowing profiles following right hemisphere stroke.

The present study employed a case report research design. This is in contrast with the vast majority of the literature on swallowing deficits following stroke, where large *N* studies have predominated. Indeed, only one other study has provided detailed description of individual

swallowing data while examining the relationship between lesion localization and swallowing impairments (Daniels & Foundas, 1997). The utility of implementing a case-by-case analysis stems from the fact that much variability exists in swallowing performance across individuals, in both health and disease. The use of group designs, while providing the power necessary to detect significant differences or relationships between variables, does not provide information regarding the extent to which variation in swallowing patterns may be related to site of brain lesion. The sequencing of oropharyngeal swallowing events has been reported to be significantly variable in healthy adults (Kendall, 2002), and yet, this variability has been the subject of relatively few studies. Given that the swallowing performance of healthy adults is highly variable, it is likely that the variability in swallowing among stroke subjects would be even greater. In fact, human stroke can be described as heterogeneous, with much variability existing in the types of stroke, recovery patterns, and related clinical factors (Gladstone, Black, & Hakim, 2002). Daniels et al. (2006) have postulated that perhaps the lack of clarity in the research examining the lateralization of the phases of swallowing is due to the great intersubject variability following stroke, and "this lack of consistent findings in the stroke literature may indicate that in some people different components of swallowing may lateralize differently..." (p.26). The present study demonstrates that individuals suffering infarcts of the same hemisphere can present with highly individualized patterns of swallowing. Continued use of case series reports may begin to reveal specific lesion sites within each hemisphere that result in similar swallowing outcomes across subjects.

Limitations of the Present Study

Because the present study examined a small number of patients, the findings should not be generalized to the population level. Rather, the results of this study are offered as descriptive "proof of principle" that both oral and pharyngeal phase swallowing deficits can occur following right hemisphere stroke. It is possible that distinct dysphagia profiles following right hemisphere stroke might begin to emerge if larger numbers of subjects were examined. In addition, it would be of great interest to use the same methodology to examine the swallowing patterns present in subjects following left hemisphere stroke and healthy age-matched controls. Most group studies have compared the swallowing performance of individuals with left versus right hemisphere stroke, but there is little information regarding the individual swallowing patterns associated with a unilateral left infarct. It is likely that a variety of swallowing patterns following left hemisphere stroke also would emerge.

Other aspects of the methodology also may have influenced the observed patterns in swallowing. For example, length of time between stroke and the modified barium swallow was variable across patients. Some of the variability in swallowing patterns may be related to the trajectory of swallowing recovery post-stroke, with

neuroplastic changes secondary to brain damage and compensatory alterations as the patient adapts to his/her new swallowing function. Nevertheless, the fact that all subjects presented with both oral and pharyngeal deficits regardless of time post-stroke provides valuable insight into the types of swallowing deficits that can be anticipated following right hemisphere stroke.

Conclusions

The results of this study suggest that both oral and pharyngeal phase swallowing deficits can occur following right hemispheric stroke. Some patients may present with a dysphagia profile characterized predominantly by impairment of the oral phase, compared to the pharyngeal phase of swallowing. Interestingly, the greatest diversity in dysphagia profiles was observed in the pharyngeal phase, with only a single parameter being common across subjects. The finding that oral phase swallowing abnormalities can be a prominent feature of right hemisphere stroke highlights the need for clinicians to remain vigilant in assessment in order to identify the breadth of deficits that may impact swallowing safety and efficiency in this patient population.

References

- Alberts, M., Horner, J., Gray, L., & Brazer, S. (1992). Aspiration after stroke: lesion analysis by brain MRI. *Dysphagia*, 7, 170-173.
- Barer, D. (1989). The natural history and functional consequences of dysphagia after hemispheric stroke. *Journal of Neurology, Neurosurgery, and Psychiatry*, 52, 236-241.
- Chen, M., Ott, D., Peele, V., & Gelfand, D. (1990). Oropharynx in patients with cerebrovascular disease: Evaluation with videofluoroscopy. *Radiology*, 176, 641-643.
- Daniels, S., Brailey, K., & Foundas, A. (1999). Lingual discoordination and dysphagia following acute stroke: Analyses of lesion localization. *Dysphagia*, 14, 85-92.
- Daniels, S., Corey, D., Fraychinaud, A., DePolo, A., & Foundas, A. (2006). Swallowing lateralization: The effects of modified dual task interference. *Dysphagia*, 21, 21-27.
- Daniels, S., & Foundas, A. (1997). The role of the insular cortex in dysphagia. *Dysphagia*, 12, 146-156.
- Daniels, S., & Foundas, A. (1999). Lesion localization in acute stroke patients with risk of aspiration. *Journal of Neuroimaging*, 9, 91-98.
- Daniels, S., Foundas, A., Iglesia, G., & Sullivan, M. (1996). Lesion site in unilateral stroke patients with dysphagia. *Journal of Stroke and Cerebrovascular Diseases*, 6, 30-34.
- Dodds, W., Logemann, J., & Stewart, E. (1990). Radiologic assessment of abnormal oral and pharyngeal phases of swallowing. *American Journal of Roentgenology*, 154, 965-974.
- Dodds, W., Stewart, E., & Logemann, J. (1990). Physiology and radiology of the normal oral and pharyngeal phases of swallowing. *American Journal of Roentgenology*, 154, 953-963.
- Gladstone, D., Black, S., & Hakim, A. (2002). Toward wisdom from failure: lessons from neuroprotective stroke trials and new therapeutic directions. *Stroke*, 33, 2123-2126.
- Gordon, C., Hower, R., & Wade, D. (1987). Dysphagia in acute stroke. *British Medical Journal*, 295, 411-414.
- Hamdy, S., Mikulis, D., Crawley, A., Xue, S., Law, H., Henry, S., & Diamant, N. E. (1999). Cortical activations during human volitional swallowing: an event related fMRI study. *American Journal of Physiology*, 277, G219-G225.
- Hamdy, S., Rothwell, J., Brooks, D., Bailey, D., Aziz, Q., & Thompson, D. (1999). Identification of the cerebral loci processing human swallowing with H215 PET activation. *Journal of Neurophysiology*, 89, 1917-1926.
- Horner, J., & Massey, E. (1988). Silent aspiration following stroke. *Neurology*, 38, 317-319.
- Horner, J., Massey, E., Riski, J., Lathrop, D., & Chase, K. (1988). Aspiration following stroke: clinical correlates and outcome. *Neurology*, 38, 1359-1362.
- Irie, H., & Lu, C. (1995). Dynamic evaluation of swallowing in patients with cerebrovascular accident. *Clinical Imaging*, 19, 240-243.
- Jean, A. (1990). Brainstem control of swallowing: localization and organization of the central pattern generator for swallowing. In A. Taylor (Ed.), *Neurophysiology of the jaws and teeth* (pp. 294-321). London: Macmillan Press.
- Johnson, E., McKenzie, S., Rosenquist, C., Lieberman, J., & Sievers, A. (1992). Dysphagia following stroke: quantitative evaluation of pharyngeal transit times. *Archives of Physical Medicine and Rehabilitation*, 73, 419-423.

- Kendall, K. (2002). Oropharyngeal swallowing variability. *Laryngoscope*, 112, 547-551.
- Logemann, J. (1998). *Evaluation and treatment of swallowing disorders* (2nd ed). Austin: Pro-Ed.
- Logemann, J., Shanahan, T., Rademaker, A., Kahrilas, P., Lazar, R., & Halper, A. (1993). Oropharyngeal swallowing after stroke in the left basal ganglion/internal capsule. *Dysphagia*, 8, 230-234.
- Martin, R., Goodyear, B., Gati, J., & Menon, R. (2001). Cerebral cortical representation of automatic and volitional swallowing in humans. *Journal of Neurophysiology*, 85, 938-950.
- Martin, R., MacIntosh, B., Smith, R., Barr, A., Stevens, T., Gati, J., & Menon, R. S. (2004). Cerebral areas processing swallowing and tongue movement are overlapping but distinct: a functional magnetic resonance imaging study. *Journal of Neurophysiology*, 92, 2428-2443.
- Martin, R., & Sessle, B. (1993). The role of the cerebral cortex in swallowing. *Dysphagia*, 8, 195-202.
- Miller, A. (1982). Deglutition. *Physiological Reviews*, 62, 129-184.
- Miller, A. (1999). *The neuroscientific principles of swallowing and dysphagia*. San Diego: Singular.
- Mosier, K., Patel, R., Liu, W., Kalnin, A., Maldjian, J., & Baredes, S. (1999). Cortical representation of swallowing in normal adults: functional implications. *Laryngoscope*, 109, 1417-1423.
- Robbins, J., & Levine, R. (1988). Swallowing after unilateral stroke of the cerebral cortex: Preliminary experience. *Dysphagia*, 3, 11-17.
- Robbins, J., Levine, R., Maser, A., Rosenbek, J., & Kempster, G. (1993). Swallowing after unilateral stroke of the cerebral cortex. *Archives of Physical Med and Rehabilitation*, 74, 1295-1300.
- Veis, S., & Logemann, J. (1985). Swallowing disorders in persons with cerebrovascular accident. *Archives of Physical Medicine and Rehabilitation*, 66, 372-375.

Author Note

This research was supported by a Heart and Stroke Foundation of Ontario Grant-In-Aid (REM), an Ontario Ministry of Energy, Science and Technology Premier's Research Excellence Award (REM), an Ontario Graduate Scholarship (JAT), and a Focus on Stroke Doctoral Research Award (JAT). The authors acknowledge the contribution of Ms. Margaret Billings in data analysis, and the participation and support of the Speech-Language Pathology Service at London Health Sciences Centre-University Hospital.

Correspondence concerning this article should be addressed to Ruth E. Martin, Faculty of Health Sciences, Elborn College, Room 2528, University of Western Ontario, London, Ontario N6G 1H1. Email: remartin@uwo.ca.

Received: September 10, 2007

Accepted: April 25, 2008



Appendix A

Table A1: Videofluoroscopic Swallow Study Rating Parameters: Oral Stage Abnormalities

Swallow Parameter	Definition
Spillage from lips	Material exits between lips during bolus preparation
Impaired bolus formation	Material not gathered into one cohesive mass
Material in lateral sulci	Material spills into lateral sulci during bolus preparation
Premature spill	Premature loss of ingested material past the anterior faucial pillars prior to onset of oral stage of swallow
Hesitancy	Delayed initiation of posterior movement of bolus following bolus preparation
Anterior tongue thrust	Anterior movement of tongue tip at onset of oral stage of swallow
Repetitive tongue pumping	Repetitive pattern in which tongue squeezes bolus posteriorly, but only to mid-palatal region, then it is rolled forward to its initial position
Uncoordinated tongue movement	Disorganized, searching tongue movements; good range of motion, but inability to organize anterior-to-posterior lingual and bolus movement
Piecemeal deglutition	After collection on superior tongue surface, bolus is divided and transported to pharynx in more than one portion
Repeated spillage	Repeated spillage of material into lateral and/or anterior sulci from superior tongue surface during oral stage of swallow
Slow oral transit	Interval from beginning of posterior movement of bolus to passage of the head of the bolus past intersection of tongue base and mandibular ramus is > 1 sec
Tongue tremor	Tongue tremor present at rest and/or on movement
Instability of mandible	Movement of mandible occurs during tongue loading/tongue propulsive stages of the oral phase
Impaired tongue stripping wave	Inefficient pattern of tongue movement along the palate resulting in incomplete and slow anterior-posterior bolus transit through oral cavity
Impaired tongue propulsive action	Reduced force, range, and/or velocity of tongue base movement to posterior pharyngeal wall during propulsion into the pharynx
Reduced tongue contact	Tongue fails to make complete contact with palatal contour or posterior pharyngeal wall (tip, dorsum, base)
Oral residue	Bolus material remains in oral cavity at termination of oral phase

Appendix A

Table A2: Videofluoroscopic Swallow Study Rating Parameters: Pharyngeal Stage Abnormalities

Swallow Parameter	Operational Definition
Absent pharyngeal phase	Rapid, coordinated movement pattern of velar elevation, hyolaryngeal elevation, UES opening, and anterior movement of posterior pharyngeal wall (PPW) does not occur
Delayed pharyngeal phase	Time (in sec) between passage of the head of the bolus past the intersection of tongue base and mandibular ramus and the onset of pharyngeal phase is > 1 sec
Reduced palatal closure	Incomplete approximation of velum and PPW at maximum velar excursion
Increased pharyngeal transit time	Time (in sec) from movement of the head of the bolus past the intersection of the tongue base and mandibular ramus to passage of the tail of the bolus through the UES is > 1 sec
Reduced pharyngeal peristalsis	Reduced anterior movement of PPW
Impaired epiglottic deflection	Epiglottis exhibits no/minimal downward deflection
Reduced laryngeal elevation	Upper outline of hyoid does not approximate the lateral contour of the mandible at maximum excursion
Impaired laryngeal vestibule closure	Incomplete closure of laryngeal vestibule during pharyngeal swallow
Laryngeal penetration	Material enters the laryngeal vestibule during pharyngeal swallow
Vallecular residue	Residual material in vallecular space following pharyngeal swallow
PPW residue	Material coats the PPW following pharyngeal swallow
Pyramidal sinus residue	Residual material in pyriform sinuses following pharyngeal swallow
Impaired UES opening	Bolus transit through the UES is impaired; material pools immediately superior to the UES
Aspiration before swallow	Material penetrates past vocal folds before the onset of the swallow
Aspiration during swallow	Material penetrates past vocal folds in the period during which the hyolaryngeal complex is elevating and descending back to rest position
Aspiration after swallow	Material penetrates past vocal folds any time after return of larynx to rest. Includes aspiration of residue associated with repeat swallow attempts
Impaired reflexive cough	Absent or delayed cough in response to laryngeal penetration and/or aspiration